



Medical Imagery

## Pale Intestinal Mucosa Below a Gastrojejunal Anastomosis – A Rare Presentation of Small Intestine Ischemia

Hsin-Chang Lin<sup>a, c, d</sup>, Chien-Yuan Hung<sup>b, c, d\*</sup>

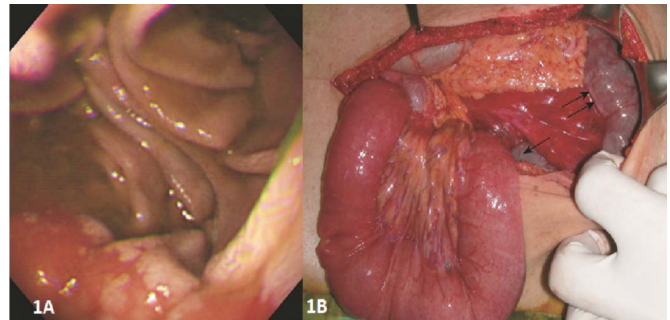
<sup>a</sup> Division of Nephrology, Department of Internal Medicine, MacKay Memorial Hospital, Taipei, Taiwan, <sup>b</sup> Division of Gastroenterology and Hepatology, Department of Internal Medicine, MacKay Memorial Hospital, Taipei, Taiwan, <sup>c</sup> MacKay Junior College of Medicine, Nursing and Management, Taipei, Taiwan, <sup>d</sup> MacKay Medical College, New Taipei, Taiwan

### ARTICLE INFO

Accepted 28 January 2019

A 79-year-old uremic patient under regular hemodialysis was hospitalized with severe postprandial epigastric pain since the previous evening. The pain was characterized as sharp and persistent. He had undergone a Billroth II gastrectomy 35 years prior for a bleeding gastric ulcer. He had no history suggestive of atherosclerotic disease, and an upper endoscopy performed one year earlier did not indicate chronic bowel ischemia. Upon examination, the patient appeared to be in severe and diffused pain. His abdomen was board-like with marked direct epigastric tenderness but no rebound tenderness. The bowel sounds were hypoactive. An upright abdominal x-ray showed no free air. An upper endoscopy was arranged to rule out peptic ulcers and demonstrated that the mucosa of the stomach remnant was hyperemic, but the intestinal mucosa below the gastrojejunal anastomosis was pale (Fig. 1A). The clear color demarcation between the stomach and jejunum suggested occlusion or interruption of the superior mesenteric artery. An operation was performed due to the persistent abdominal pain.

During the operation, a strangulated internal hernia was noted in the small bowel, which was purple and congested (Fig. 1B). Release of the hernia restored adequate circulation, and resection was unnecessary. The pancreaticoduodenal arcades and dorsal pancreatic artery are collaterals between the superior mesenteric artery and celiac trunk. When they are transected during gastrectomy, it creates a watershed territory between the superior mesenteric and



**Fig. 1.** (A) A 79-year-old uremic patient underwent a Billroth II gastrectomy 35 years previously for a bleeding gastric ulcer. The endoscopic view of the gastric remnant mucosa was hyperemic, but the intestinal mucosa below the gastrojejunal anastomosis was pale. (B) A strangulated internal hernia involved the small bowel, the affected small bowel was purple and congested (arrows).

celiac arteries. The patient's pale jejunal mucosa suggested ischemic injury confined to the inner layers of the bowel wall, an indicator of early hypoperfusion due to strangulation.<sup>1</sup> Endoscopic findings in ischemic enteritis are not absolutely pathognomonic, however, so there should be a low threshold for surgical intervention to avert intestinal gangrene.

### Reference

1. Herman J, Chavalitdhamrong D, Jensen DM, et al. The significance of gastric and duodenal histological ischemia reported on endoscopic biopsy. *Endoscopy*. 2011;43:365–368.

\* Corresponding author. Division of Gastroenterology and Hepatology, Department of Internal Medicine, MacKay Memorial Hospital, No.92, Sec. 2, Chung-Shan North Road, Taipei, Taiwan.

E-mail address: [hungchienyuan@yahoo.com.tw](mailto:hungchienyuan@yahoo.com.tw) (C.-Y. Hung)